Reviews in Infection RIF

RIF 1(2):104-109 (2010) ISSN:1837-6746

Case Report

Corynebacterium striatum: Chronic infection of a cutaneous ulcer in a patient with AIDS

Edward J. Bottone, PhD[a*], Marilyn Fabbri, MD[b], Amar Ashraf, MD[b]

[a]Division of Infectious Disease, The Mount Sinai Hospital, New York, New York 10029, USA
[a]Departments of Medicine and Pathology, New York Medical College, Valhalla, New York 10595, USA
[b]Division of Infectious Disease, Elmhurst Hospital Center, Elmhurst, New York 11373, USA

*Corresponding Author: edward.bottone@mssm.edu

Abstract

We describe an unusual case of *C. striatum* chronic infection of a cutaneous ulcer in a patient with AIDS. The bacterium was considered etiologically significant after scrapings of the lesion showed numerous gram-positive bacilli on smear, and culture rendered heavy growth of only *C. striatum*. Treatment with vancomycin was curative.

Keywords: AIDS; Chronic Infection; Corynebacterium striatum; Cutaneous Ulcer

Introduction

Corynebacterium other than *C. diphtheriae* referred to as "diphtheroids" are often regarded as normal inhabi tants of the human skin. Of the 17 *Corynebacterium* species, three, *C. jeikeium, C. urealyticum*, and more recently *C. striatum* have garnered medical interest due to an evolving number of publications referable to community acquired and nosocomial infections (Brandenberg et al.,1996: Iaria et al., 2007: Lee et al., 2005: Martinez-Martinez et al., 1994, Martinez-Martinez et al., 1997: Otsuka et al., 2006: Renum et al., 2007). *C. jeikeium* is well-characterized as a pathogen in neutropenic hosts (Van der lelie et al., 2005) and those with prosthetic devices and indwelling catheters. Interest in *C. striatum,* as a multidrug-resistant nosocomial pathogen has also been associated with infections in patients with medical devices (Lee et al 2005), endocarditis (Boltin et al., 2009, Marull and Casares, 2008), pulmonary infections (Renom et al., 2007; Tarr et al., 2003; Martinez-Martinez et al., 1994; Batson et al., 1996) and with rare episodes of septic synovitis (Cone et al., 1998), and meningitis (Weiss et al., 1996). The spectrum of infections has led to the recognition of *C. striatum* as a bona-fide human community and nosocomial pathogen (Lee et al., 2005). Herein we report a case of chronic cutaneous ulcer in an AIDS patient due to *C. striatum* and discuss its diagnosis, treatment and review its role as a cutaneous pathogen.

Case Report

The patient is a 53-year-old female smoker with HIV/AIDS, with a CD 4 count of 275 cells'mm^3 and undetectable viral load on antiretroviral therapy. She has history of COPD, peripheral vascular disease, hepatitis C and she was previously an intravenous drug user. In April 2007 she presented to the Infectious Disease Clinic with a painful nonhealing ulcer with surrounding cellulitis over the lateral aspect of her right ankle. Upon questioning the patient reported trauma to that area which resulted from her wearing a boot for five consecutive days due to snow. Swabbings of the lesion sent for culture grew *Corynebacterium* species, *Staphylococcus epidermidis* and *Pseudomonas aeruginosa.* The *Corynebacterium* was not further speciated because it was regarded as a contaminant. The patient was treated with multiple courses of antibiotics including ceftin, ciprofloxacin, and clindamycin with no improvement. MRI performed at that time revealed no evidence of osteomyelitis. The patient was subsequently seen in microbiologic consultation at which time careful

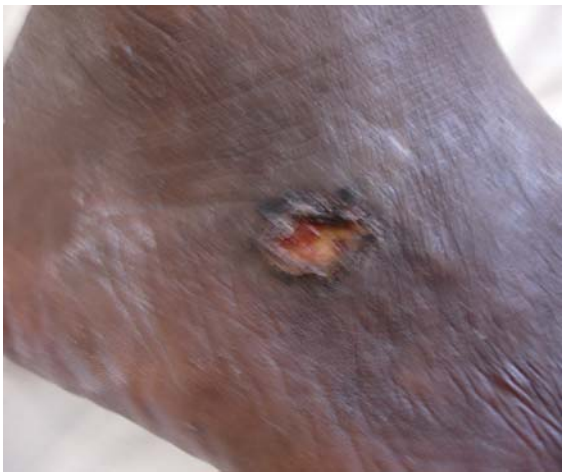

Fig 1. Painful, chronic 1 cm ulcer with surrounding cellulitis on lateral aspect of right ankle.

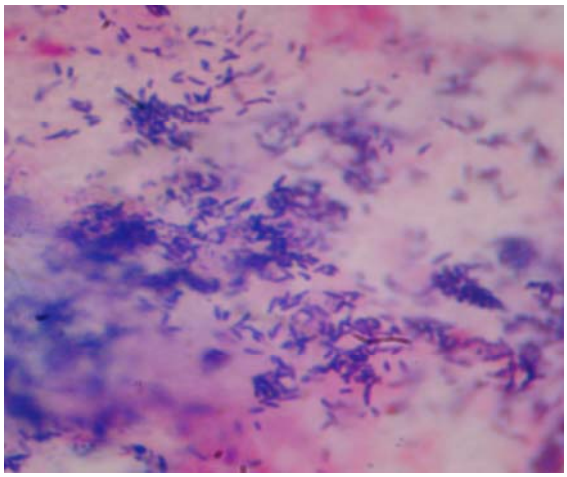

Fig 2. Gram stain of scraping of cutaneous ulcer showing innumerable short gram-positive bacilli in clusters and in palisade formation.

scrapings of the lesion were collected for Gram stain and culture which grew only *Corynebacterium striatum.* The patient was treated with a two week course of oral linezolid with no improvement in the ulcer prompting admission to the hospital in July . On examination there was a 1 cm ulcer over her right lateral malleolus with surrounding erythema, tenderness and purulent drainage (Figure 1). Gram-stained smears and culture were repeated which again revealed only *Corynebacterium striatum*. Her right dorsalis pedis and posterior tibial pulses were palpable but femoral pulse was absent. She was started on a two week course of vancomycin and oral metronidazole which resulted in complete resolution of the ulcer. A CT angiogram performed during her hospitalization disclosed a severe right common artery stenosis and a stent was placed after hospital discharge.

Microbiology

Gram-stained smears of scrapings of the ulcerative lesion on both occasions showed the overwhelming presence of gram-positive bacilli with clubbed ends and in palisade formation (Figure 2). Many of the bacilli were visualized within polymorphonuclear leukocytes (Figure 3). Direct inoculation of the scrapings onto 5% sheep blood agar on both occasions grew pure cultures of white-to-cream colored, nonhemolytic, smooth colonies reminiscent of those produced by coagulase-negative *Staphylococcus* species (Martinez-Martinez et al 1995) , (Figure 4). Gram stained smears of colony growth showed gram-positive bacilli some of which upon careful evaluation showed a striped pattern.

In addition to microscopic and colony morphology, the nonmotile, catalase positive isolate was identified as *C. striatum* through the use of the RapID CB Plus system (Remel, Leonexa, KS). The salient reactions were glucose and sucrose fermentation, nitrate reduction and negative urease production. The RapID CB Plus system resulting pattern of negative and positive scores was 3007551 which correlated with *C. striatum* in the manufacturers data base. Antimicrobial susceptibility performed by ETest strips (AB BIODISK Solna, Sweden) and using guidelines according to Clinical Laboratory Standards institute (CLSI) showed the isolate to be resistant to penicillin, clindamycin, and tetracycline, but susceptible to vancomycin (MIC 0.25 µg)

Discussion

For many years *Corynebacterium striatum* was long believed to have limited potential as a pathogen and hence was usually considered a contaminant when isolated from a patient specimen. Evidence to support the role of *C. striatum* as a pathogen in immu-nocompromised and immunocompetent hosts is growing. The role of *C. striatum* as a nosocomial pathogen is also evolving as it has been reported in several hospital outbreaks (Brandenburg et al., 1996; Creagh et al., 2000; Iaria et al 2007; Mashavi et al., 2005; Otsuka et al., 2006; Renom et al.,2007) In one surgical ICU outbreak, (Brandenburg et al., 1996). a single strain was isolated from clinical specimens of 14 patients over a 12-month period. Ten of the isolates (sputum, blood, and wounds) recovered from six patients were regarded as significant. The outbreak strain was isolated from surfaces and from

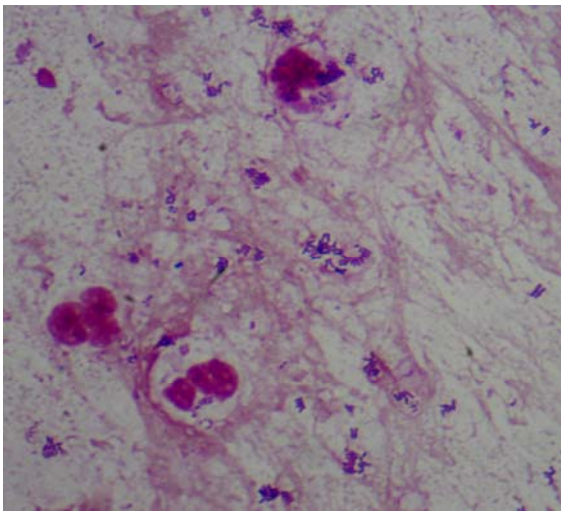

Fig 3. Gram stain of ulcer scraping showing small clusters of gram-positive bacilli within polymorphonuclear leukocytes

Fig 4. Soft opaque colonies at sites of direct inoculation of scrapings from ulcerative skin lesion

air in the direct vicinity of the patients and also on the hands of hospital personnel suggesting a role in patient to patient transfer. As a colonizer of human skin *C. striatum* can establish de novo cutaneous infections through disruption of intact skin barriers as in our case, or can invade preexisting cutaneous lesions. Watkins et al (1993) in his series of six cases included one of a 78-year-old women with a history of colorectal cancer who punctured her finger on a rose bush thorn and developed a pyogenic granuloma. Culture of the biopsy specimen resulted in heavy growth of *C. striatum* and *P. aeruginosa*. Surgical incision without antibiotics resolved the soft tissue mass. Peris et al. (1994) described a 73-year-old woman with peripheral vascular disease who was noted to have a deep skin sinus around her elbow which was oozing pus. The sinus tract had been present for months and developed in the absence of overt trauma. Culture of the exudate "recovered heavy pure growth of *C. striatum.* A similar case of a *C. striatum* infected ischemic ulcer in a 72-year-old diabetic patient was included among the series of 26 cases described by Martinez-Martinez 1997. A case report by Martin et al. clearly demonstrated the skin was the portal of entry for a *C. striatum* septicemic episode in a 69-year-old patient with chronic ischemia of the lower extremities and lesions in the first and second toe and heel of the right foot. Molecular analysis utilizing two DNA fingerprinting techniques, ribotyping and randomly amplified polymorphic (RAPD) analysis, were used to confirm the identical nature of the strains isolated from the patient's blood and foot lesions. Resolution of the infection took place with the administration of intravenous amoxicillin-clavulanic acid and the placement of a femoral bypass. In our patient it is conceivable that her cutaneous ulcer was also attributable to an ischemic incident induced by the uninterrupted insertion of her foot in a boot for five days. A minor break in her skin during this time period could have provided a portal of entry for *C. striatum* perhaps colonizing her skin. Furthermore, Superti et al., (2009) reported a *C. striatum* skin and soft tissue infection of a malignant skin lesion in a 27-year-old male patient further indicating that this bacterium has a predilection for devitalized cutaneous tissue. Most *C. striatum* infections take place in patients with underlying medical conditions. In a series reported by Martinez-Martinez et.al, 1997, 26 patients with positive *C. striatum* cultures were identified as having significant infections as defined by CDC criteria. In seven of the 26 patients, the organism was isolated from a culture of a chronic skin ulcer and another seven had surgical wound infections. Associated conditions in this set of patients included diabetes, cirrhosis, chronic renal failure, trauma, surgery, and malignancy. Patients were treated with either surgical intervention, antibiotic therapy, or both. The majority of patients who completed follow-up were cured or improved.

C. striatum infections involving the skin have also been reported in normal hosts. A recurring breast abscess that required several drainage procedures over a seven week period was described in a 41 year old immunocompetent woman with no underlying medical conditions. (Stone et al.,1997). Microscopy of excised tissue after her second procedure when the

wound became necrotic showed large numbers of gram-positive bacilli on Gram stain and heavy growth of *C. striatum* on culture. These data finally prompted effective treatment with intravenous oxytetracycline to which the isolate was susceptible. The abscess healed within six weeks. Cone et al. (1992) reported a case of a 51-year-old healthy physician who accidentally lacerated his left elbow with a scalpel blade that had passed through a patient's skin. Three days later the physician was diagnosed with septic arthritis of the elbow requiring surgical drainage. Although Gram stain of the purulent exudate revealed only a few polymorphonuclear leukocytes, culture grew *C. striatum*. The key to diagnosis in these and other patients was the recognition of *C. striatum* as a pathogen because of the abundance of organisms seen on Gram stain, some within polymorphonuclear leukocytes, and dominant growth in culture. *Corynebacterium* species have also been reported to cause serious infections in patients who are infected with HIV. Among these are *Corynebacterium pseudodiptheriticum* (Cohen et al., 1992; Guiterrez et al., 1999), *Corynebacterium jeikeium* (Sanchez-porto et al., 1994; Turett et al., 1993), *Corynebacterium urealyticum* (Aracil et al., 1997), *Corynebacterium minutissimum* (Bandera et al., 2000) and *Corynebacterium afermentans* (Minkin and Shapiro 2004). These *Corynebacterium* species have all been reported as etiologic agents of pulmonary infections (Minkin and Shapiro 2004 (Cohen et al., 1992) bacteremia (Sanchez-porto et al., 1994; Aracil et al. 1997), liver abscess (Turett et al.1993) and costochondral abscess (Bandera et al., 2000). There have been only two case reports of *C. striatum* infections in AIDS patients. Tumbarello et al., (1994) described a 26-year-old male drug abuser with AIDS and cerebral toxoplasmosis necessitating a central venous catheter be placed to stabilize his condition. Twelve days later he became febrile and three blood cultures grew *C. striatum* which was successfully treated by removal of the central line and a 3 week course of teicoplanin The second case report (Creagh et al., 2000) involved a 28 year-old male drug user with AIDS, Hepatitis B and C, who presented with alveolar and interstitial infiltrates that responded poorly to ceftriaxone and ceftazidime. Bronchoscopy with bronchoalveolar lavage was performed with isolation of pure cultures of *C. striatum*. Pulmonary mycobacterial and fungal cultures, and studies for *Pneumocytis jiroveci* and *Legionella pneumophila* were negative. The patient improved clinically and radiographically with an antibiotic regimen including vancomycin, imipenem and erythromycin followed by teicoplanin and erythromycin. The diagnosis and treatment of the patient in our case report was delayed for several reasons. The *C. striatum* initially isolated on wound culture was dismissed as a contaminant because it was from a non-sterile site and because the *Corynebacterium* species was viewed as a colonizer. The resistant nature of this isolate prevented an initial response to empiric ciprofloxacin and ceftin that were given. There are limited reports on the antibiotic susceptibility pattern of *C. striatum.* A study conducted by Martinez-Martinez et al. (1996) of 86 *C. striatum* isolates from clinical specimens showed uniform susceptibility of the isolates to penicillin, cefazolin, imipenem, vancomycin and teicoplanin. In the same study, co-trimoxazole, tetracycline, ciprofloxacin, erythromycin and rifampin were found to have poor activity against *C. striatum*. Antibiotic susceptibility cited in several case reports and series have described multidrug resistant isolates (Iaria et al.2007; Marull et al., 2008; Mashavi et al. 2005; Otsuka et al., 2006; Renom et al., 2007; Tarr et al., 2003, Tumbarello et al., 1994). In some cases vancomycin was considered the only active agent (Renom et al., 2007; Mashavi et al., 2005). More recently, Fernandez-Roblas et al. (2009) studied the *invitro* activity of tigecycline and 10 other antimicrobial agents against 11 *C. striatum* isolates by ETest strips (AB BIODISK Solna, Sweden).Using Clinical and Laboratory Standards Institute (CLSI) guidelines, the authors concluded that the isolates were uniformly susceptible to tigecycline, vancomycin, linezolid, penicillin and quinupristin-dalfopristin, but resistant to erythromycin, azithromycin, clarithomycin, and clindamycin.

Corynebacterium striatum is now an established pathogen in immunocompromised and in some settings, immunocompetent hosts. Isolation of *C. striatum* from a clinical specimen in a patient with suspected infection should not be ignored. Evidence of large numbers of organisms on Gram stain or predominant growth in culture, or bacteremia, support its role as a potential pathogen. The antibiotic susceptibility of *C. striatum* is variable and empiric therapy with a glycopepetide should be considered while awaiting the susceptibility pattern of a particular isolate.

References

Aracil B., Perea B., Barros C., Gómez-Garcés JL (1997) Bacteremia caused by *Corynebacterium urealyticum* in 2 patients co-infected with HIV and HBV. Enferm Infecc Microbiol Clin. 15:172-3.

Bandera A, Gori A, Rossi MC, Degli Esposti A, et al. (2000) A case of costochondral abcess due to *Corynebacterium minutissimum* in an HIV infected patient. J Infect 41:103-5.

Batson JH, Mukkamala R, byrd Jr. RP, Roy TM (1996) Pulmonary abscess due to *Corynebacterium striatum*. J Tenn Med Assoc 89:115-116.

Boltin D, Katzir M, Bugoslavsky V, Yalashvili I, Brosh-Nissimov T, Fried M, Elkayam O (2009) *Corynebacterium striatum*: a classic pathogen eluding diagnosis. European J. Int. Med.20:e49-52.

Brandenburg AH, van Belkum A, van Pelt C, Bruining A, Mouton JW, Verbrugh HA (1996) Patient-to-patient spread of a single Strain of *Corynebacterium striatum* causing infections in a surgical intensive care unit. J. Clin. Microbiol. 34:2089-94.

Cohen Y, Force G, Gros I, et al. (1992) *Corynebacterium pseudodiphteriticum* pulmonary infection in AIDS patients. Lancet 340:114-5.

Cone LA, Curry N, Wuestoff MA, O'Connell SJ, Feller JF (1998) Septic synovitis and arthritis due to *Corynebacterium striatum* following an accidental scalpel Injury. Clin Infect Dis 27:1532-3.

Creagh R, Saavedra JM, Rodriguez FJ, Rodriguez P, Merino D (2000) Pneumonia caused by *Corynebacterium striatum* in a patient with AIDS. Enferm Infecc Microbiol Clin. 18:297 298.

Fernandez-Roblas R, Adames H, Martín-de-Hijas NZ, Garcia Almeida D, Gadea L, Esteban J (2009) In vitro activity of tigecycline and 10 other antimicrobials against clinical isolates of the genus *Corynebacterium*. Int J Antimicrob Ag 33:453-455

Guiterrez-Rodero F, Ortiz de la Tabla V, Martínez C, et al. (1999) *Corynebacterium pseudodiphteriticum*: an easily missed respiratory pathogen in HIV-infected patients. Diagn Microbiol Infect Dis. 33:209-16.

Iaria C, Stassi G, Costa GB, Biondo C, Gerace E, Noto A, Spinella SG, David A, Cascio A (2007) Outbreak of multi-resistant *Corynebacterium striatum* in an Italian general intensive care unit. J Hosp Infect. 67:102-4.

Lee PP, Ferguson Jr. DA, Sarubbi FA. (2005) *Corynebacterium striatum*: an underappreciated community and nosocomial pathogen. J Infect 50:338-343

Leonard RB, Nowowiejski DJ, Warren JJ, Finn DJ Coyle MB (1994) Molecular evidence of person-to-person transmission of a pigmented strain of *Corynebacterium striatum* in intensive care units. J Clin Microbiol 28:8-10.

Martin MC, Melón O, Celada MM, Alvarez J Méndez FJ, Vázquez F (2003) Septicemia due to *Corynebacterium striatum*: molecular confirmation of entry via the skin. J Med Microbiol. 52:599-602.

Martínez-Martínez L, Suárez AI, Rodríguez-Baño J, Bernard K Muniain MA (1997) Clinical significance of *Corynebacterium striatum* isolated from human samples. Clin Microbiol Infect 3: 634-369.

Martínez-Martínez L, Pascual A, Bernard K, Suárez AI (1996) Antimicrobial susceptibility pattern of *Corynebacterium striatum*. Antimicrob Ag Chemother 40:2671-2672.

Martinez-Martinez L, SuárezAI, Winstanley J, Ortega MC, Bernard K (1995) Phenotypic characteristics of 31 strains of *Corynebacterium striatum* isolated from clinical specimens J Clin Microbiol 33:2458-2461.

Martinez-Martinez L, Suárez AL, Ortega MC, Rodriguez-Jiménez R (1994) Fatal pulmonary infection caused by *Corynebacterium striatum*. Clin Infect Dis 19:806-807

Marull J, Casares PA (2008) Nosocomial valve endocarditis due to *Corynebacterium striatum*: a case report. Cases J. 1:388.

Mashavi M, Soifer E, Harpaz D, Beigel Y (2005) First report of prosthetic mitral valve endocarditis due to *Corynebacterium striatum*: successful medical treatment. Case report and literature review. J. Infect. 52:e139-141.

Minkin R, Shapiro JM. (2004) *Corynebacterium afermentans* lung abscess and empyema in a patient with human immunodeficiency virus infection. South. Med. J. 97:395-7.

Otsuka Y, Ohkusu K, Kawamura Y Baba S, Ezaki T, Kimura S (2006) Emergence of multidrug-resistant *Corynebacterium striatum* as a nosocomial pathogen in long-term hospitalized patients with underlying diseases. Diag Microbiol Infect Dis 54:109-114.

Peiris V, Fraser F, Knowles C, Norris S, Bennett C (1994) Isolation of *Corynebacterium striatum* from three hospital patients. Eur J Clinical Microbiol Infect Dis 13:36-38

Renom F, Garau M, Rubí M, Ramis F, Galmés A, Soriano JB (2007). Nosocomial outbreak of *Corynebacterium striatum* in patients with chronic obstructive pulmonary disease. J Clin Microbiol 45:2064-2067.

Sánchez-Porto A, Vergara de Campos A, Iñigo MA, Torres-Tortosa M, Rodriguez-Iglesias M (1994) Bacteremia caused by *Corynebacterium jeikeium* in 2 AIDS patients without neutropenia. Enferm Infecc Microbiol Clin. 12:31-33.

Stone N, Gillett P, Burge S. (1997). Breast abscess due to *Corynebacterium striatum*. Brit J Dermatol 137:623-625.

Superti S V, Martins D S, Caierã J, Soares F, Prochnow T, Cantarelli V V, Zavascki A P (2009) *Corynebacterium striatum* infecting a malignant cutaneous lesion: the emergence of an opportunistic pathogen. Rev Inst Med Trop Sao Paulo 51:115-116.

Tarr PE, Stock F, Cooke RH, Fedorko RH, Lucey DR (2003) Multidrug-resistant *Corynebacterium striatum* pneumonia in a heart transplant recipient. Transpl Infect. Dis. 5:5358.

Tumbarello M, Tacconelli E, Del Forno A, Caponera S, Cauda R (1994) *Corynebacterium striatum* bacteremia in a patient with AIDS. Clin Infect Dis. 18:1007-1008

Turett GS, Fazal BA, Johnston BE, (1993). Liver abscess due to *Corynebacterium jeikeium* in a patient with AIDS. Clin. Infect. Dis. 17:514-5.

Van der Lelie, M. et al.(1995). *Corynebacterium* CDC group J. K. (*Corynebacterium Jeikeium)* sepsis in hematological patients: a report of three cases and a systematic literature review. Scand. J. Infect. Dis. 27: 581-584.

Watkins DA, Chahine A, Creger RJ, Jacobs MR, Lazarus HM (1993) *Corynebacterium striatum*: a diphtheroid with pathogenic potential Clin Infect Dis 17:21-25.

Weiss K, Labbé AC, Laverdiēre M (1966) *Corynebacterium striatum* meningitis: case report and review of an increasingly important *Corynebacterium* species Clin Infect Dis 23:1246-1248.